

## C A S E R E P O R T

# Management of intersection syndrome in professional motorcycle rider: a case report

Letizia Marenghi<sup>1,2</sup>, Giulia Mainardi<sup>1</sup>, Michele Zasa<sup>1,3</sup>

<sup>1</sup>Clinica Mobile nel Mondo, World Motorbike Championships (MotoGP & WSBK) Medical Division, Parma, Italy; <sup>2</sup>Azienda Ospedaliero-Universitaria di Parma, Parma, Italy; <sup>3</sup>Curriculum of Sport Sciences and Physical Exercise, Department of Medicine and Surgery, University of Parma, Parma, Italy

**Summary.** *Background and aim of the work:* Intersection syndrome is an uncommon and underdiagnosed condition, especially found in sport overuse. This case report describes the treatment of a professional motor biker who presented intense wrist pain and swelling after training sessions. *Methods:* The athlete was treated with rest, the use of a wrist splint combined with NSAIDs, physical therapy, including pulsed Nd-YAG laser therapy and exercise, such as stretching and release, massage and eccentric training. *Results:* The applied therapeutic protocol was successful and allowed the biker to completely resolve the symptoms and return to training session and professional races at full power. The results are durable at 5 months post injury follow up. *Conclusions:* This experience suggests that pulsed Nd-YAG laser therapy can be an additional useful tool in the global approach treatment for intersection syndrome, contributing with splint and manual therapy, to full recovery even in mechanically stressful conditions. ([www.actabiomedica.it](http://www.actabiomedica.it))

**Key words:** intersection syndrome, wrist pain, pulsed Nd-YAG laser therapy, tendons

## Introduction

Intersection syndrome is a relatively uncommon overuse inflammatory syndrome which is often undiagnosed (1). This condition is associated with repeated radial deviation of the wrist and has been identified with a number of different names peritendinitis crepitans, bugaboo forearm, abductor pollicis longus bursitis, crossover syndrome, Oarsman's wrist, adventitial bursitis, subcutaneous perimyositis (2).

Intersection syndrome is a tendinitis with unclear pathophysiology affecting the first and second dorsal compartment. This condition is associated with the frequent and repetitive use of the wrist and it is more common in athletes (3). Possible explanations of the origin of this condition are related to the inflammation caused by friction between the extensor carpi radialis longus and extensor carpi radialis brevis where they cross under abductor pollicis longus (APL) and exten-

sor pollicis brevis (EPB) muscle bellies in the second dorsal compartment approximately (2). Another hypothesis is related to the narrowing of the sheaths of the extensor carpi radialis longus and the extensor carpi radialis brevis tendons, leading to swelling and pain.

Differential diagnosis includes mainly De Quervain syndrome but also tenosynovitis of other extensor tendons, blunt local trauma, or entrapment of the dorsal radial sensory nerve, ganglion cysts, infections, sprains involving the ligaments of the wrist, muscle strains, soft-tissue tumors (4).

In most of the cases, intersection syndrome responds favorably to conservative treatment, non-responders have to undergo surgery (5) to decompress the cross-over point via tenosynovectomy or fasciotomy of the abductor pollicis longus (6). Examples of conservative therapy which have been used to treat this condition are rest (2, 4), application of ice, NSAIDs (7), wrist splinting (8), corticosteroid injection, etc.

Prevalence in the general population, varies between 0.20% and 0.37%.

High-intensity laser therapy (HILT) by pulsed Nd:YAG laser is used in physical therapy and rehabilitation. Clinical studies and scientific literature support the anti-inflammatory, anti-edematous, pain relief, and analgesic effects of Nd:YAG laser. Examples of successful clinical use of this therapy range from sub-acromial impingement syndrome to cervical pain (9, 10).

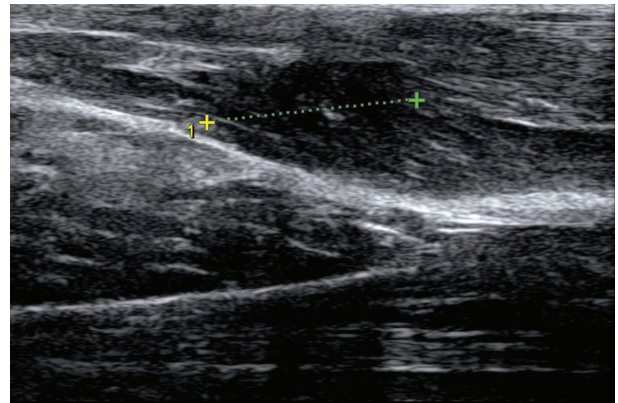
We often use pulsed Nd-YAG laser therapy for the treatment of tendonitis and muscle contractures in professional bikers with positive results in terms of pain management and patient acceptance. In this case report the specific use of pulsed Nd-YAG laser therapy, along with manual therapy, was carried out to solve an insertion syndrome in a professional biker.

### Case report

Patient description: 22 years old Moto2 professional biker (weight: 69 Kg, height: 183 cm). His standard training activities include Flat Track, Moto-cross, Motard and gym exercise.

During a Flat Track training session, the biker started perceiving a mild pain at the left forearm. He reported that the circuit was quite difficult and stabilizing the bike required a large effort. During the same evening, pain intensity had a peak, therefore the biker decided to have 2 days of rest. After the rest, the painful symptoms disappeared, but as soon as the sport activity started again, the pain returned. Specifically, the pilot run 50 laps and then stopped for lunch, complaining about stinging pain. During the afternoon training, swelling of the forearm started. The biker decided to discontinue the training session and immediately proceed with a manual therapy session on site. The next day, pain was so intense that the biker was able to complete 5 laps only. The personal driving style, based on upper limb use mainly, has never caused any problem up to that moment in the biker's career.

The intersection syndrome diagnosis has been based on the clinical assessment of the patient and ultrasounds images (Fig. 1), reporting a minimal reaction of edematous type of the extensors of the periskel-



**Figure 1.** Ultrasound image revealing minimal reaction of edematous type of the extensors of the periskel-etal muscle sleeve

etal muscle sleeve. Doppler image (data not shown) shows the inflammatory reaction. Patient complained about stinging pain at the left forearm with peaks in stressful conditions, but present daily and persistent in days of maximum acuity. The clinical examination revealed pain in the following situations: palpation of the forearm radial surface, at 4 cm proximally to the radial styloid; thumb mobilization; wrist radial extension. Swelling and crepitus to mobilization of wrist and thumb were present in the same area. In days of maximum pain, this was perceived all day long, while proceeding with therapy, pain was only perceived in stressful conditions. The specific feature of this clinical case is related to the fact that once treatment has started, pain was present only under stressful conditions, which is quite unusual in tendon pathologies that are typically symptomatic until complete healing.

Counselling has been provided to the biker in order to explain most common causes of tenosynovitis and potentially avoid future re-occurrence. The first treatment step involved rest and the use of a splint including wrist in extension and the first finger. Initially, NSAID use was prescribed daily and then, in parallel to symptoms remission, upon need. The patient had not been fully compliant with the complete rest prescription and the splint wearing instruction, using the device discontinuously.

The patient underwent pulsed Nd:YAG laser treatment (Hilterapia®, ASA Srl, Arcugnano, Italy). The technical characteristic of Hilterapia® are the following: pulsed emission (1,064 nm), brief duration

(120-150  $\mu$ s), low frequency (10-40 Hz), duty cycle of about 0.1%.

The laser probe was applied perpendicularly to and in slight contact with the skin. The total energy delivered to the patient during the sessions was on average 1600J in three phases of treatment.

The first phase involved fast manual scanning over the interested forearm. An average total energy dose of 600J was administered in this phase.

The second phase involved application to the trigger points and the surrounding area. An average total energy dose of 400J was administered in this phase.

The third phase involved slow manual scanning over the interested forearm. An average total energy dose of 600J was administered in this phase.

Seven pulsed Nd-YAG laser therapy sessions were performed in a period of 8 weeks. Due to the specific Grand Prix schedule, the treatments were performed during 3 race weekends and had 4 week breaks in between. Two treatments were performed in the first two race weekends, three treatments were performed during the third and last weekend. Stretching and release of the involved muscles were carried out during the session. Each laser treatment was associated to manual therapy, such as massage and eccentric training.

All laser applications were performed by the same physiotherapist.

Given that once treatment has started, at rest no painful sensation was reported by the subject, actual pain improvement evaluation was to be postponed until the patient next bike training or exercise. This patient feedback was important to follow up patient progress in between treatments.

The clinical results that have been obtained were considered optimal by the patients. In fact, after 8 weeks from treatment start, pain has completely disappeared, even under stressful conditions, and the biker has been able to come back to usual training program and competition. Swelling and crepitus have fully disappeared. Complete wrist and thumb active range of motion (AROM) has been recovered without pain, even against resistance.

At 5-month follow up, the results are durable, especially during sport activities requiring tendon involvement.

## Discussion

In intersection syndrome, pain is the key factor, along with swelling and crepitus upon palpation and/or movement. In the reported case, the patient was unable to carry out his professional sport activity due to the increasing pain that he was experiencing. At the same time, the patient needed to achieve complete pain remission as quickly as possible in order to proceed with scheduled races. The treatment approach started with patient education, discussing with the biker the details of the condition and potential etiological factors. Therapeutic plan has been based on the combination of different strategies including traditional tools such as rest, which anyway was only providing temporary relief, and the use of a splint, which obtained limited patient compliance. The patient was suggested to take NSAIDs to manage acute pain which was persistent in the first phase of the treatment. The use of rest, ice and NSAIDs represent the most common conservative approach to intersection syndrome (4, 5) and it is common to the management of most overuse syndromes. Symptoms resolve within 2 to 3 weeks for 60% of patients with rest, administration of nonsteroidal anti-inflammatory drugs, and splinting. Physical therapies including manual therapy and high intensity laser therapy were added in order to improve healing time. In many cases, the alternative to avoid surgical procedure (4), when the first approach to conservative treatment is not satisfying is related to corticosteroid injections (5) adjacent to the area of maximum swelling.

Pulsed Nd-YAG laser therapy demonstrated to be a beneficial tool for the conservative treatment of insertion syndrome, in combination with manual therapy and NSAIDs assumption to manage pain peak. The possible mechanism for the action of pulsed Nd-YAG laser therapy in intersection syndrome is related to its anti-inflammatory properties (11), which have been documented in scientific studies along with its anti-oedemogenic and analgesic effects (12, 13).

High intensity laser therapy thanks to its anti-inflammatory properties can be a beneficial tool in the conservative management of intersection syndrome in athletes. The present case suggests that the appropriate treatment approach, integrating traditional and inno-

vative tools, allows for a full recovery with no relapses, even when sport activity is started again extensively.

**Conflict of interest:** None to declare

## References

1. Palmer DH, Lane-Larsen CL. Helicopter skiing wrist injuries: a case report of 'bugaboo forearm.' *Am J Sports Med* 1994; 22(1): 148-9.
2. Howard NJ. Peritendinitis crepitans. *JBJS* 1937; 19: 447-59.
3. Adams JE, Habbu R. Tendinopathies of the hand and wrist. *J Am Acad Orthop Surg* 2015; 23: 741-50.
4. Idler RS, Strickland JW, Creighton JJ Jr. Intersection syndrome. *Indiana Med*.1990; 83: 658-9.
5. Balakatounis K, Angoules AG, Angoules NA, Panagiotopoulou K. Synthesis of evidence for the treatment of intersection syndrome. *World J Orthop* 2017 Aug 18; 8(8): 619-623.
6. Stern PJ. Tendinitis, overuse syndromes, and tendon injuries. *Hand Clin* 1990; 6: 467-76.
7. Lee RP, Hatem SF, Recht MP. Extended MRI findings of intersection syndrome. *Skeletal Radiol* 2009; 38(2): 157-63.
8. Jean Yonnet G. Intersection syndrome in a handcyclist: case report and literature review. *Top Spinal Cord Inj Rehabil* 2013; 1: 236-24
9. Santamato A, Solfrizzi V, Panza F et al. Short-term Effects of High-Intensity Laser Therapy Versus Ultrasound Therapy in the Treatment of People With Subacromial Impingement Syndrome: A Randomized Clinical Trial. *Physical Therapy* 2009; 89(7): 643-52.
10. Alayat MSM, Atya AM, Ali MME, Shosha TM. Long-term effect of high-intensity laser therapy in the treatment of patients with chronic low back pain: a randomized blinded placebo-controlled trial. *Lasers Med Sci* 2014; 29(3): 1065-73.
11. Zati A, Degli Esposti S, Bilotta TW. Il laser CO2: effetti analgesici e psicologici in uno studio controllato. *Laser & Technology* 1997; 7: 723-30.
12. Viliiani T, Ricci E, Mangone G, Graziani C, Pasquetti P. Effects of Hilterapia vs. Viscosupplementation in knee osteoarthritis patients a randomized controlled clinical trial. *Energy for Health* 2009; 3: 14-7.
13. Kheshie AR, Alayat MS, Ali MM. High-intensity versus low-level laser therapy in the treatment of patients with knee osteoarthritis: a randomized controlled trial. *Lasers Med Sci* 2014; 29(4): 1371-6.

Received: 14 October 2018

Accepted: 11 April 2019

Correspondence:

Marengi Letizia,

Via Gramsci 14 - 43125 Parma, Italy

Tel. 0521702142

E-mail: letiziamarengi@gmail.com